


# Decompressive craniectomy: Indication, technique, present status and controversies



# History

---

- ▶ Decompressive craniotomy first described by Annandale in 1894
- ▶ Performed as palliative procedure for inoperable brain tumor
- ▶ Kocher(1901) first proposed DC as treatment of raised ICP
- ▶ Cushing – sub temporal and sub occipital decompression
- ▶ Now a days , DC as treatment modality of raised ICP , and most controversial of all



# Pathophysiology of raised ICP

---

- ▶ ICP is pressure within cranial vault, a rigid structure
- ▶ Contents -
  - Brain parenchyma
  - CSF
  - Blood
- Beyond compensatory mechanisms rise in any of these, will increase ICP exponentially – Monro - Kellie doctrine.

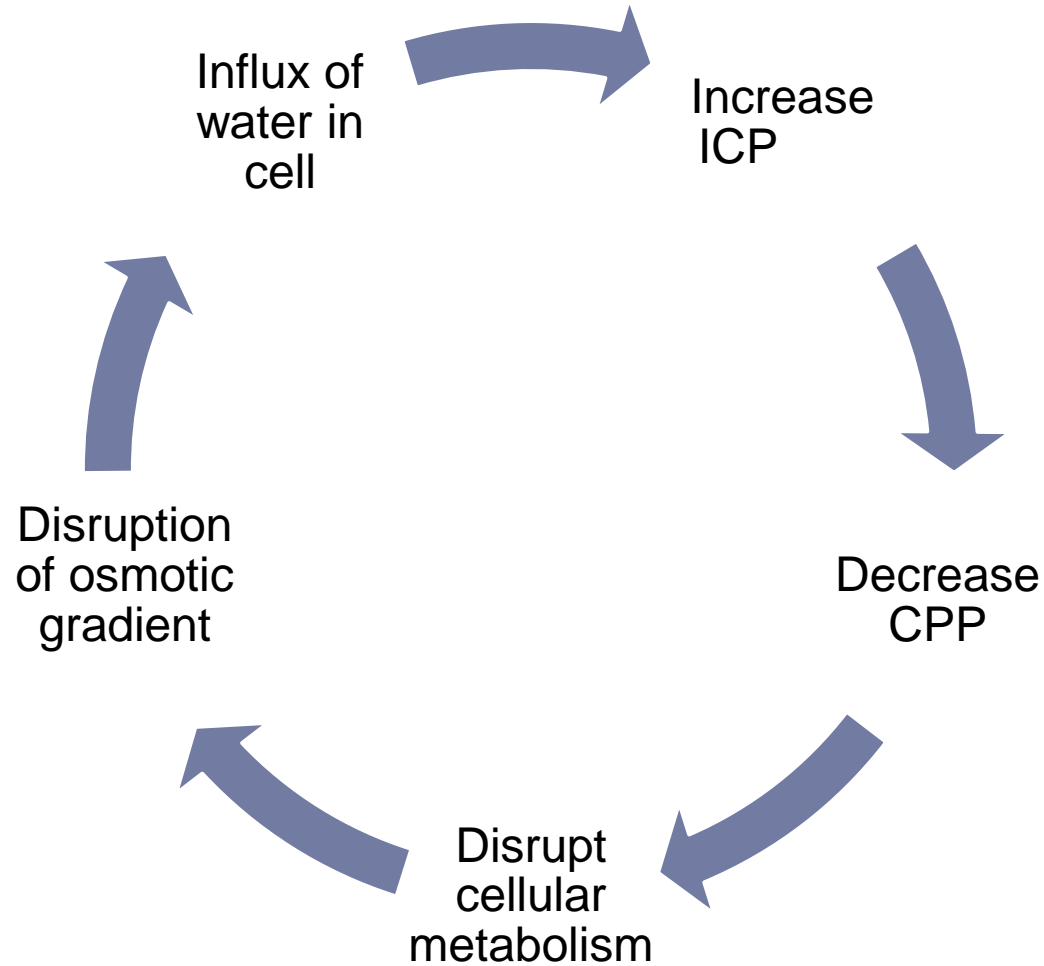


- 
- ▶ ICP is one of factor that governs cerebral perfusion pressure .
  - ▶  $CPP = MAP - ICP$
  - ▶ Any increase in ICP beyond compensatory mechanism will decrease in CPP .



# Feed forward cycle of raised ICP

---



- 
- ▶ Cranial vault compartmentalized by thick dural folds like falx, tentorium.
  - ▶ Raised ICP leads to herniation across these compartments .
  - ▶ Herniation distort vascular anatomy and CSF flow pathways leading to further increase in ICP .



# Role of DC

---

- ▶ Increases buffering capacity of cranium.
- ▶ Allow outward herniation, preventing compression of brainstem structures and reconstruct brain perfusion
- ▶ ICP reduction vary from 15-85% depending on size of bone removed.
- ▶ Durotomy further decreases ICP.



# Indication of DC

---

- ▶ Traumatic brain injury
- ▶ Malignant cerebral infarction
  
- ▶ Others – Cerebral venous sinus thrombosis, intracerebral hematoma, metabolic encephalopathies .





# Role of DC in Traumatic brain injury

---

- ▶ TBI is the most common indication for decompressive craniectomy
- ▶ Pathophysiology of TBI –
  - Primary injury
  - Secondary injury
- Secondary injury is amenable to treatment, aim of the treatment is to prevent secondary injury.



# Recommendation of brain trauma foundation

---

- ▶ General maneuvers –  
head elevation & neutral position (to avoid venous congestion)  
normothermia,  
sedation,  
volume resuscitation
  - ▶ First line therapy – CSF drainage, hypocapnia (PaCo<sub>2</sub> 30-35mmHg), mannitol administration
  - ▶ Second tier – high dose barbiturates, intense hyperventilation (PaCo<sub>2</sub> <30mmHg), increase in mean arterial pressure, mild to moderate hypothermia, decompressive craniectomy
-

# Types of DC

---

- ▶ Primary or prophylactic DC
  
- ▶ Therapeutic decompression or secondary decompressive craniectomy – continuous ICP monitoring is conducted and ICP is refractory to medical treatment.



# Types of DC

---

- ▶ Prophylactic or primary decompressive craniectomy  
- any surgical decompression performed, with or without brain tissue removal, in patients undergoing surgery primarily for the evacuation of any type of intradural lesion.
- ▶ The aim of prophylactic craniectomy is not to control refractory ICP but to avoid increase in ICP.
- ▶ Decision taken based on CT, not on ICP



# TBI in pediatric population

---

- ▶ Taylor et al (2001) – prospective, randomized controlled trial in patients <18 yrs old
- ▶ 27 patients randomized
  - 14 – medical treatment , 13 – bitemporal DC
- ▶ The risk of death in participants treated with DC was lower than that of patients treated with maximal medical treatment (RR 0.54, 95%CI 0.17 to 1.72).
- ▶ The risk of unfavourable outcome (death, vegetative status, or severe disability) was also lower in the DC group than in the control group (RR 0.54, 95% CI 0.29 to 1.01).

Decompressive craniectomy for the treatment of refractory high intracranial pressure in traumatic brain injury (Review) 29

Copyright © 2009 The Cochrane Collaboration

---



# TBI in Adults

---

- ▶ Various studies demonstrate DC improves ICP, cerebral oxygenation, cerebral compliance

*J. Neurosurg. / Volume 108 / May 2008, Effect of decompressive craniectomy on intracranial pressure and cerebrospinal compensation following traumatic brain injury J.*

*Neurosurg. / Volume 108 / May 2008, Cerebral oxygenation, vascular reactivity, and neurochemistry following decompressive craniectomy for severe traumatic brain injury*



- 
- No evidence to support the routine use of secondary DC to reduce unfavourable outcome in adults with severe TBI and refractory high ICP.
  - ▶ In the pediatric population DC reduces the risk of death and unfavourable outcome.

The Cochrane Database of Systematic Reviews

*The Cochrane Library, Copyright 2006,*

*The Cochrane Collaboration Volume (1), 2006*

Decompressive craniectomy for the treatment of refractory high intracranial pressure in traumatic brain injury


Sahuquillo, J; Arikian, F

**Decompressive craniectomy for the treatment of refractory high intracranial pressure in traumatic brain injury  
(Review)**

Copyright © 2009 The Cochrane Collaboration

---



- 
- ▶ DECRA trial (DEcompressive CRAniectomy in patient with severe traumatic brain injury )
  - ▶ RESCUEIcp (Randomized Evaluation of Surgery with Craniectomy for Uncontrollable Elevation of ICP)
- 
- 



# DECRA trail

---

- ▶ Multicenter, randomized, controlled Decompressive Craniectomy (DECRA) trial to test the efficacy of bifrontotemporoparietal decompressive craniectomy in adults under the age of 60 years with traumatic brain injury in whom first-tier intensive care and neurosurgical therapies had not maintained intracranial pressure below accepted targets.

Decompressive Craniectomy in Diffuse Traumatic Brain Injury . N Engl J Med. 2011 Apr 21;364(16):1493-502.

---



# Study Design

---

- ▶ Dec 2002- April 2010 , 15 tertiary care centres in Australia, New Zealand, Saudi Arabia
- ▶ Inclusion criteria
  - Age 15-59 yrs
  - Non penetrating traumatic brain injury
  - GCS 3-8
  - Marshall class III (moderate diffuse injury on CT)
- Exclusion – dilated non reactive pupil, mass lesion, spinal cord injury or cardiac arrest at scene



# Treatment protocol

---

- ▶ Standard treatment Vs surgery + standard treatment
- ▶ With in 72 hrs
- ▶ ICP measurement in all patient (12 before and 36 hrs after randomization)
- ▶ Surgery – bifrontotemporopareta craniectomy with bilateral Dural opening (modified Polin technique) . Sagittal sinus and falx not divided.
- ▶ Results compared based on extended Glasgow outcome scale at 6 months.



# Results

---

| Characteristic                         | Surgery group(73) | Standard(82) | Significance |
|--|-------------------|--------------|--------------|
| Age (median)                           | 23.7 y            | 24.6 y       | no           |
| GCS / motor                            | 5 / 3             | 6 / 3        | no           |
| Cause of injury                        |                   |              | no           |
| Marshall class III                     | 53                | 53           | no           |
| Time of injury to hospitalization (hr) | 1                 | 1.2          | No           |
| Time of Injury to randomization(hr)    | 35.2              | 34.8         | no           |
| Reactivity of pupil (neither)          | 27%               | 12%          | yes (p-0.04) |



# Results

---

|                                 | <b>Surgery</b> | <b>standard</b> | <b>Significance</b> |
|---------------------------------|----------------|-----------------|---------------------|
| Mean ICP after randomization    | 14.4 mmHg      | 19.1mmHg        | yes                 |
| Intracranial HTN index          | 11.5           | 19.9            | Yes                 |
| Duration of ventilation (days)  | 11             | 15              | Yes                 |
| Duration of ICU stay(days)      | 13             | 18              | yes                 |
| Duration of hospital stay(days) | 28             | 37              | no                  |
| Extended GOS score (1-4)        | 51(70%)        | 42(51%)         | P-0.02              |

The intracranial hypertension index is the number of end-hourly measures of intracranial pressure of more than 20 mm Hg divided by the total number of measurements, multiplied by 100.



- 
- ▶ DECRA trail - In adults with severe diffuse traumatic brain injury and refractory intracranial hypertension, early bifrontotemporoparietal decompressive craniectomy decreased intracranial pressure and the length of stay in the ICU but was associated with more unfavourable outcomes .

Decompressive Craniectomy in Diffuse Traumatic Brain Injury . N Engl J Med. 2011 Apr 21;364(16):1493-502.

---



# RESCUEicp trial

---

- ▶ Ongoing
- ▶ Aim –

Provide class I evidence as to whether decompressive craniectomy is effective for the management of patients with raised and refractory ICP following traumatic brain injury (TBI).

| Inclusion  | Exclusion   |
|--|---|
| Age 10-65 yrs                                    | Mass lesion                                       |
| Icp >25mmHg, after refractory first line therapy | Tt with barbiturates pre-randomization            |
|  | Bilateral fixed dilated pupils                    |
|  | Bleeding diathesis                                |
|  | Devastating injury not expected to survive 24 hrs |

- 
- ▶ Target - Total 400 patients (200 in each group)
  - ▶ Outcome measured at 6 months with Glasgow outcome scale score
  
  - ▶ Results so far – 280 pt recruited , follow up – 96%  
evaluation of first 182 patients shows  
equal distribution of characteristics

*Critical Care 2011, Volume 15 Suppl 1 PJ Hutchinson1, AG Koliass1, I Timofeev1, E Corteen1, M Czosnyka1,DK Menon2, JD Pickard1, PJ Kirkpatrick1 1Academic Division of Neurosurgery, Addenbrooke's Hospital & University of Cambridge, UK; 2Neurocritical Care Unit & University Department of Anaesthesia, Addenbrooke's Hospital & University of Cambridge, UK Critical Care 2011, 15(Suppl 1):P312 (doi: 10.1186/cc9732)*

---





# Present status of DC in TBI

---

- ▶ Pediatric population – DC reduces risk of death and unfavorable outcome
- ▶ For adults - Role of DC in raised ICP due to TBI as second tier treatment is still controversial.



# Malignant cerebral infarction

---

- ▶ Large territorial parenchymal infarction with post ischemic edema and associated with uncal or axial herniation.
- ▶ Occlusion of proximal MCA, more than 50% of supplied territory involved.
- ▶ Treatment – medical management or surgery (decompressive craniectomy)
- ▶ Surgery – clearly reduce mortality however survivors suffered high morbidity .

Rishi Gupta, E. Sander Connolly, Stephan Mayer and Mitchell S.V Elkind. **Hemicraniectomy for Massive Middle Cerebral Artery Territory Infarction : A Systematic Review** *Stroke* 2004, 35:539-543:

---



- 
- ▶ 3 RCTs conducted and results published.
  - ▶ DECIMAL (DEcompressive Craniectomy In MALignant middle cerebral artery infarction)
  - ▶ DESTINY (DEcompressive Surgery for Treatment of INfarction of malignant middle cerebral artery)
  - ▶ HAMLET ( Hemicraniectomy After Middle cerebral artery infarction with Life –threatening Edema Trial )



| Study Name | Year | No. of Pts | Inclusion Criteria                              | Time to Tx (hrs) | Primary Outcome Measure                 | Mortality (%) |         | Good Outcome |         |
|------------|------|------------|---|------------------|---|---------------|---------|--------------|---------|
|            |      |            |   |                  |   | Surgical      | Medical | Surgical     | Medical |
| DESTINY    | 2007 | 32         | age 18–60 yrs, NIHSS >18–20, >2/3 MCA territory | 36               | death at 30 days, mRS score <4 at 6 mos | 17.6          | 53.0    | 47.0         | 27.0    |
| DECIMAL    | 2007 | 38         | age 18–55 yrs                                   | 24               | mRS score <4 at 6 mos                   | 25.0          | 77.8    | 50.0         | 22.2    |
| HAMLET     | 2009 | 64         | age 18–60 yrs                                   | 96               | mRS score <4 at 12 mos                  | 22.0          | 59.0    | 25.0         | 25.0    |

---

▶ Good outcome – mRS scale 1-4

▶ Bad outcome – mRS scale 5-6

| Score | Definition  |
|-------|---|
| 0     | asymptomatic  |
| 1     | no significant disability; able to carry out all usual activities,  |
| 2     | despite some symptoms<br>slight disability; able to look after own affairs w/o assistance,                              |
| 3     | but unable to carry out all previous activities<br>moderate disability; requires some help, but able to walk unassisted |
| 4     | moderately severe disability; unable to attend to own bodily needs w/o assistance, unable to walk unassisted            |
| 5     | severe disability; requires constant nursing care & attention, bedridden, incontinent                                   |
| 6     | dead  |



# Result

---

- ▶ Only patient underwent decompression within 48 hrs were considered for pooled analysis .
- ▶ total 109 – Surgery- 58, Medical -51
- ▶ Effect on mortality -
- ▶ DECIMAL – absolute reduction in risk 53% at 6 months
- ▶ DESTINY – 12% mortality in surgical and 53% in medical group at 30 days
- ▶ HAMLET – 38% reduction in risk at 1 year




# Results

---

- ▶ Effect on mortality – all 3 trial shows significant reduction in mortality.
- ▶ Absolute reduction in mortality is 49.9%
- ▶ Effect on severe disability (mRS score 5) – absolute reduction in risk of bad functional outcome was 41.9% .
- ▶ Conclusion - surgical decompression with in 48 hrs of onset of stroke reduced risk of significant morbidity.



- 
- ▶ Effect on moderately severe disability(mRS score 4)
    - none of 3 trials showed statistically significant conclusion favoring good functional outcome
  - ▶ Disability in survivors - while demonstrating an undeniable increase in the number of survivors among surgical patients, also showed an increase in the number of survivors with moderately severe disability (mRS score of 4).
- 
- 



- 
- ▶ Laterality of DC – DECIMAL trail shows no difference in mRS score of survivors with or without aphasia at 1 yr.
  - ▶ Size of craniectomy – 12 cms diameter , FTP region reaching up to floor of middle fossa, avoiding

midline.  
Wagner S, Schnippering H, Aschoff A, Koziol JA, Schwab S, Steiner T: Suboptimum hemicraniectomy as a cause of additional cerebral lesions in patients with malignant infarction of the middle cerebral artery. **J Neurosurg** 94:693–696, 200



- 
- ▶ Timing of surgery – optimal time window ?
  - ▶ HeADDFIRST (Hemicraniectomy And Durotomy on Deterioration From Infarction Related Swelling Trial)  
window period – 96 hrs
  - ▶ HeMMI trial (Hemicraniectomy for Malignant Middle cerebral artery Infarcts) time period of 72 hrs.
  - ▶ Age of patient - <60 yrs.  
DESTINY II – ongoing to study effect of Surgery in older

pt >60 yrs



# Conclusion (present status)

---

- ▶ Pooled analysis of all 3 trials provides Class I evidence for the performance of early decompressive craniectomy in the setting of large unilateral infarcts (volume > 145 cc) within 48 hours of the ischemic event.
- ▶ Further studies are needed to better define quality of life issues at long-term follow-up as well as age limit issues.

**Neurosurg Focus 30 (6):E18, 2011** Decompressive hemicraniectomy after malignant middle cerebral artery infarction: rationale and controversies **Omar M. Arnaout, M.D., Salah G. Aoun, M.D., H. Hunt Batjer, M.D., and Bernard R. Bendo k, M.D.** *Department of Neurological Surgery, Feinberg School of Medicine and McGaw Medical Centre, Northwestern University, Chicago, Illinois*

---



# Technique of decompressive craniectomy

---

- ▶ Fronto-temporo-parietal approach
- ▶ Bifrontal decompressive approach
- ▶ Temporal approach



# FTP approach

---

- ▶ Unilateral lesion with contra lateral herniation
- ▶ Bone exposure-
  - superior border of orbital roof (avoid frontal sinus)
  - 2 cms lateral to midline
  - 2 cms posterior to external auditory meatus
  - to floor of middle fossa
- ▶ Size of craniectomy – 10 x 15 cms , lower margin extending less than 1 cms of middle cranial fossa



- 
- ▶ Small size craniectomies associated with pericraniectomy hemorrhage and infarct ( diameter < 8 cms)
  - ▶ Lower margin of craniectomy with floor of middle cranial fossa correlates with state of mesencephalic cisternal decompression



- 
- ▶ FTP decompressive craniectomy – 92.6 cm<sup>3</sup>
  - ▶ large fronto-temporoparietal decompressive craniectomy (standard trauma craniectomy) significantly improved the outcome in severe TBI patients with refractory intracranial hypertension, compared with routine temporoparietal craniectomy, and had a better effect in terms of decreasing ICP

Jiang JY, Xu W, Li WP, et al. Efficacy of standard trauma craniectomy for refractory intracranial hypertension with severe traumatic brain injury: a multicenter, prospective, randomized controlled study. *J Neurotrauma* 2005;22:623-628.

---



# Opening of Dura

---

- ▶ Enhances further decrease in ICP
- ▶ Only durotomy without duraplasty –
  - risk of herniation of parenchyma
  - epilepsy
  - CSF leak
- Durotomy with augmentative duraplasty recommended





- 
- ▶ Temporal decompression – area 26-33 cm<sup>3</sup>  
(Cushing) decrease ICP  
unable to improve blood  
flow  
and  
temporal lobe herniation  
necrosis

Alexander E, Ball MR, Laster DW. Subtemporal decompression: radiology observations and current experience. Br J Neurosurg 1987;1:427-433.

---



# Bi Frontal approach

---

- ▶ Diffuse Traumatic Brain Injury
- ▶ Polin technique – anteriorly roof of orbit,  
posteriorly 3-5 cms behind coronal  
suture  
base of temporal bone
- Saggital sinus ligation and division



- 
- ▶ Lobectomy / contusectomy - Adequate excision of brain contusion is a useful adjuvant in the management of severe head injury with contusions.
  - ▶ Rapid closure - is feasible and safe in decompressive craniectomy. The surgical time is significantly shorter without increased complication rates or additional complications.
  - ▶ Cranioplasty after a RCDC procedure was also feasible, fast, safe and not impaired by the RCDC technique.

Rapid closure technique in decompressive craniectomy **J Neurosurg**  
**114:954–960, 2011y**

---



# AIIMS study

---

## **Factors Affecting the Outcome of Patients Undergoing Decompressive Craniectomy in Severe Head Injury– A Prospective Analysis**

- ▶ DEC 2007 to DEC 2009
  - ▶ Inclusion criteria – Acute SDH with or without parenchymal injury with midline shift and effacement of ambient cistern
    - Exclusion – diffuse axonal injury , GCS>8 ,  
Hypoxic brain damage
- 



- 
- ▶ Observation and results – total 334 ,  
survived – 131, death – 203
  - Demographic parameters – male 289 (86.53%)  
female 45 (13.47%) ,
  - ▶ Sex and mode of injury had no statistical  
significance
  - Age – significantly affect outcome . Old age  
associated with poor outcome.
- 
- ▶

# Clinical parameters

---

- ▶ Reactivity of pupils and pre-op GCS had statistical significance .
- ▶ Pre-op GCS 3,4,5 – survived 23.02%
- ▶ Pre-op GCS 6,7,8 – survived 49.04%
- ▶ ENT bleed, seizure, respiratory distress , hypotension had no statistical significance .
- ▶ Radiological parameters – Acute SDH with infarct only significant parameter.
- ▶ Degree of MLS, thickness of SDH, contusion are not significant .



# Operative parameters

---

| Surgery   | Survived    | Death       |
|---|-------------|-------------|
| DC with lax duraplasty (257)                            | 100(38.91%) | 157(61.09%) |
| DC with lax duraplasty with lobectomy/contusectomy (61) | 30(49.18%)  | 31(50.82%)  |
| Dc with duratomy (16)                                   | 1(6.25%)    | 15(93.75%)  |

